



International Journal of Current Research and Academic Review

ISSN: 2347-3215 Volume 3 Number 8 (August-2015) pp. 1-6

www.ijcrar.com



An investigation on mast cells count in oral reactive lesions

Molouk Torabi Parizi^{1*}, Mehrnaz Karimi Afshar⁴, Maryam Rad², Ali Taheri³ and Ramin Afshar Manesh⁴

¹Kerman Oral and Dental Diseases Research Center, Department of Pathology, School of Dentistry, Kerman University of medical Sciences, Kerman, Iran

²Candidate of Oral Epidemiology, Kerman Oral and Dental Diseases Research Center, Kerman University of Medical Sciences, Kerman, Iran

³Department of Pathology, School of Dentistry, Kerman University of medical Sciences, Kerman, Iran

⁴Dentist

*Corresponding author

KEYWORDS

Reactive lesions,
Mast cell,
Oral mucosa,
Soft tissue,
Toluidine blue

A B S T R A C T

The aim of this study was to investigate and compare mast cells count in oral soft tissue reactive lesions. In this study, 100 paraffin embedded samples from oral pathology department which includes inflammatory fibrous hyperplasia, irritation fibroma, peripheral giant cell granuloma and peripheral ossifying fibroma (25 samples each) were selected. Ten normal gingival tissues were considered as the control group. Tissues stained with toluidine blue and mast cells were counted in 5 HPF. The data was analyzed in SPSS software by using linear regression test and P values of 0.05% were considered as significant. Approximately 65.7% of lesions were in female and the mean age of samples was 37.6 ± 16.9 . The mean number of mast cells in reactive lesion was significantly higher than normal mucosa (5.27 ± 3.83 versus 1.12 ± 0.56). There was not significant correlation between sex and age and the mean number of mast cells. Also, there was no significant difference between the mean of mast cells and the type of lesions. The findings of the present study suggested that mast cells may play a role in oral reactive lesions and further study is recommended.

Introduction

Mast cells are granulated cells that have immunoglobulin E receptor on their surface and are another source of vasoactive mediator, especially in response to allergens (Rubin *et al.*, 2005). Mast cells are seen in all of connective tissues, particularly in

mucosa of lung, digestive system, skin, and capillary vessels (Rubin *et al.*, 2005; Lunderius-Andersson *et al.*, 2012; Theoharides *et al.*, 2007). When mast cells are activated by antigens, inflammatory mediators in cytoplasm granules consist of

mucopolysaccharide acid, serine protease, histamine and chemotactic mediators from neutrophils and eosinophils are released to extracellular tissues. Mast cells degranulation may be triggered by factors such as cold, trauma, and cationic proteins, secreted from platelets and neutrophil lysosomes. Histamine increases vascular permeability and, by attaching to H1 receptors, causes vasoconstriction and edema. Mast cells have an important role in vascular permeability regulation (Rubin *et al.*, 2005), and can regulate immune system in immunity disorders, through releasing mediators such as leukotrienes, histamine, cytokines, chemokines, chymase, and tryptase (Amin, 2012). Mast cells hyperplasia is common in fibrotic tissues and they synthesize many profibrotic mediators (Monument *et al.*, 2010). It is shown that cyclosporine inhibits mast cell degranulation or release of mast cell mediators (Krishnaswamy *et al.*, 2001).

Santos and *et al.* (2011) showed that the number of mast cells in giant cell fibroma are lower than inflammatory fibrous hyperplasia and suggested that mast cells have a role in fibrous induction and function regulation of endothelial cells in giant cell fibroma (Santos *et al.*, 2011). Kamal *et al.* (2011) maintained that mast cells number is higher in pyogenic granuloma compared with normal mucosa. They concluded that mast cells may have a role in angiogenesis and recruitment of inflammatory cells in oral pyogenic granuloma (Kamal *et al.*, 2011). It is shown that mast cells have a role in fibrotic capsule of cystic lesions formation, and also in collagen formation is due to releasing heparin, hyaluronic acid, proteoglycans, proteolysis enzymes, and fibroblastic growth factor (Dračić *et al.*, 2010; Ahmed *et al.*, 2009; de Assis Caldas Pereira *et al.*, 2012). Oral reactive lesions are the most common oral soft tissue lesions and represented as a hyperplastic soft tissue

in response to irritation or chronic trauma. Despite of chronic irritation factors, as common etiologic factors, they have different histopathologic characteristics (Neville *et al.*, 2009). The aim of the present study was mast cells count in oral inflammatory reactive lesions.

Materials and Methods

In this cross-sectional study 100 embedded paraffin blocks from irritation fibroma, pyogenic granuloma, inflammatory fibrous hyperplasia, peripheral ossifying fibroma (25 block from each), as well as 10 normal oral mucosa as control samples obtained from oral pathology department were selected. Five micron thickness was prepared from each sample. For detection of mast cells sections were stained with toluidine blue. Mast cells were counted in 10 HPF, blindly by two pathologists using an optical microscope (Olympus, BX-41, Japan), and the mean number of mast cells were considered. The data were analyzed statistically using T test, ANOVA and linear regression. P value of 0.05% was considered significant level. Demographic data (sex, age, lesion location) were obtained from patients' records.

Results and Discussion

The findings of this study are as follows

Thirty four and three percent of lesions in this study were observed in men and 65.7% in women with a mean age of 37.6 ± 16.9 years. The average number of mast cells in all lesions was 5.27 ± 3.38 . The most number of mast cells were seen in peripheral ossifying fibroma (no: 16) and the lowest (no:3) in peripheral giant cell granuloma. Minimum age of patients was 10 years (in pyogenic granuloma) and the maximum age was 81 years (in inflammatory fibrous hyperplasia), respectively. Table 1 shows

the mean age of subjects based on type of lesion. Also, the mean and standard deviation of mast cells based on the type of lesion is shown in table 2. There was no significant difference between the mean of mast cells and the type of lesions. Multivariate analysis showed that there was no significant association between sex and age of patients and the mean number of mast cells ($P = 0.52$, $P = 0.96$) respectively). Figures 1 and 2 show the mast cells in pyogenic granuloma and irritation fibroma.

The present study was to evaluate the number of mast cells in oral peripheral reactive lesions of the oral cavity. Mast cells are the main source of histamine, proteinase, and other important chemical mediators. Tryptase enzyme is found exclusively in these cells. Mast cells have different biological activities including Fibrinogenesis, stimulates proliferation fibroblasts, smooth muscle cells, and bronchial epithelium (Caughey, 2007; Kondo *et al.*, 2001; Shimizu *et al.*, 2004).

It is assumed that tryptase secreted from mast cells may stimulate collagen synthesis and is involved in angiogenesis (Shimizu *et al.*, 2004; Huttunen and Harvima, 2005). The findings of the present study indicate that mast cells from normal mucosa were significantly higher in the oral lesions. Gunhan and colleagues (1989) showed that the number of mast cells in gingival hyperplastic mucosa and pyogenic granuloma were higher than that in normal mucosa, also Shahrabi *et al.* (2010) showed that, the number of mast cells in reactive oral mucosal lesions were greater than in normal mucosa, which is similar to the present study. In the present study, the highest mean number of mast cells (6.90 ± 3.73) was observed in inflammatory fibrous hyperplasia, although this difference was not significant. Santos *et al.* (2011) and Shahrabi *et al.* (2010) concluded that the

largest number of mast cells were observed in inflammatory fibrous hyperplasia which is similar to the present study. It is shown that tryptase and chymase secreted from mast cells induced fibroblast proliferation and collagen type 1 synthesis (Riekkii *et al.*, 2004). In the present study, not significant difference was observed between the number of mast cells in irritation fibroma, a reactive lesion that has relatively higher stromal collagen, compared to other peripheral inflammatory lesions and other lesions. Shahrabi *et al.* (2010) also showed that the number of mast cells in irritation fibroma was lower than that of peripheral ossifying fibroma. This could be due to sample size limitation or stage of maturity of the lesion during surgical procedure. Murata demonstrated that the maximum role of mast cells are observed in the neovascularization stage of granulation tissue and their number is reduced in fibrosis stage (Murata *et al.*, 1997).

Epithelial cells, as well as macrophages and mast cells, are able to produce mast cells' fibrinogenic cytokines (Roberts and Brenchley, 2000). In the present study, the mean number of mast cells in peripheral ossifying fibroma was significantly greater than peripheral giant cell granuloma, similar to the results obtained by Shahrabi *et al.* (2010). This study showed that mast cells number was significantly greater in pyogenic granuloma than in normal mucosa, which is consistent with findings of Kamal *et al.* (2011). Glowacki and Mulliken (1982) in their study showed that the average count of mast cells in hemangiomas were greater than vascular proliferation and suggested that release of mediators from mast cells may lead to neoangiogenesis. The increased number of mast cells in pyogenic granuloma compared to that of normal mucosa supported the role of mast cells in the pathogenesis of oral pyogenic granuloma.

Conclusion

This study showed that the number of mast cells in reactive oral cavity lesions is similar

to other investigation. Further studies on larger samples are recommended.

Table.1 The mean age of subjects based on type of lesion

lesion	Mean age	Standard deviation
Peripheral ossifying fibroma	32.20	12.90
Peripheral giant cell granuloma	37.90	9.75
Irritation fibroma	39.40	13.62
Inflammatory fibrous hyperplasia	65.90	9.53
Pyogenic granuloma	27.20	14.69

Table.2 The comparison of the different types of lesions with normal mucosa according to the mean of mast cell numbers

lesion	Mean of mast cells no.	Standard deviation	P value
Peripheral ossifying fibroma	6.88	4.50	0.007*
Peripheral giant cell granuloma	2.16	1.09	0.008*
Irritation fibroma	3.57	2.61	0.012*
Inflammatory fibrous hyperplasia	6.90	3.73	0.001*
Pyogenic granuloma	5.55	3.35	0.002*
Normal oral mucosa	1.12	0.56	

*Significant difference with normal mucosa

Figure.1 Mast cells (arrows) in a case of Pyogenic Granuloma (Toluidine blue, *100)

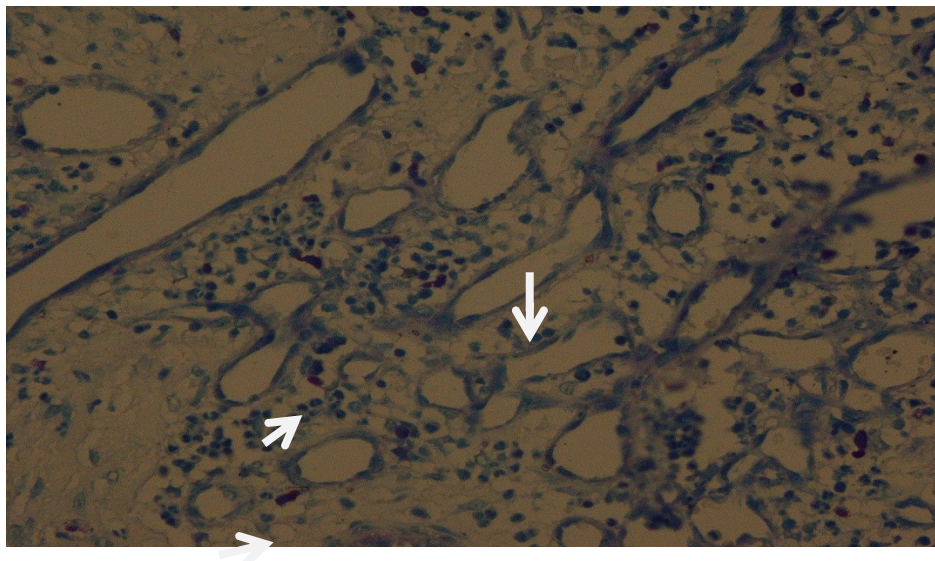



Figure.2 Mast cells (arrows) in a case of Irritation Fibroma (Toluidine blue, *100)



References

- Ahmed, A., Powers, M.P., Youker, K.A., *et al.* 2009. Mast cell burden and reticulin fibrosis in the myeloproliferative neoplasms: a computer-assisted image analysis study. *Pathol. Res. Pract.*, 205: 634–8.
- Amin, K. 2012. The role of mast cells in allergic inflammation. *Respir. Med.*, 106(1): 9–14.
- Caughey, G.H. 2007. Mast cell tryptases and chymases in inflammation and host defense. *Immunol. Rev.*, 217: 141–54.
- de Assis Caldas Pereira, Gurgel C AS, Vidal MTA, dos Santos JN. Distribution of mast cells in benign odontogenic tumors. *Tumor Biol.*, 33: 455–461.
- Dražić, R., Sopta, J., Minić, A.J. 2010. Mast cells in periapical lesions: potential role in their pathogenesis. *J. Oral Pathol. Med.*, 39(3): 257–62.
- Glowacki, J., Mulliken, J.B. 1982. Mast cells in hemangiomas and vascular malformations. *Pediatrics*, 70: 48–51.
- Gunhan, M., Bostanci, H., Gunhan, O. 1989. Mast cell counting in fibrous gingival hyperplasia and giant cell granuloma, Ankara Univ. *Hekim Fak Derg*, 16: 435–436.
- Huttunen, M., Harvima, I.T. 2005. Mast cell tryptase and chymase in chronic leg ulcers: chymase is potentially destructive to epithelium and is controlled by proteinase inhibitors. *Br. J. Dermatol.*, 152: 1149–60.
- Kamal, R., Dahiya, P., Palaskar, S., Shetty, V.P. 2011. Comparative analysis of mast cell count in normal oral mucosa and oral pyogenic granuloma. *J. Clin. Exp. Dent.*, 3(1): e1–4.
- Kondo, S., Kagami, S., Kido, H., Strutz, F., Muller, G.A., Kuroda, Y. 2001. Role of mast cell tryptase in renal interstitial fibrosis. *J. Am. Soc. Nephrol.*, 12: 1668–76.
- Krishnaswamy, G., Kelley, J., Johnson, D., Youngberg, G., Stone, W., Huang, S.K., Bieber, J., Chi, D.S. 2001. The human mast cell: functions in physiology and disease. *Front Biosci.*, 6: D1109–27.
- Lunderius-Andersson, C., Enoksson, M., Nilsson, G. 2012. Mast cells respond

- to cell injury through the recognition of IL-33. *Front. Immunol.*, 3: 82.
- Monument, M.J., Hart, D.A., Befus, A.D., Salo, P.T., Zhang, M., Hildebrand, K.A. 2010. The mast cell stabilizer ketotifen fumarate lessens contracture severity and myofibroblast hyperplasia: a study of a rabbit model of posttraumatic joint contractures. *J. Bone Joint Surg. Am.*, 92(6): 1468–77.
- Murata, M., Hara, K., Saku, T. 1997. Dynamic distribution of basic fibroblast growth factor during epulis formation: an immunohistochemical study in an enhanced healing process of the gingiva, *J. Oral. Pathol.*, 26: 224–232.
- Neville, B.W., Damm, D.D., Allen, C.M., Bouquot, J.E. 2009. Oral and maxillofacial pathology, 3rd edn., Chapt. 12. Saunders, St. Louis. Pp. 507–522.
- Riekkki, R., Harvima, I.T., Jukkola, A., Risteli, J., Oikarinen, A. 2004. The production of collagen and the activity of mast-cell chymase increase in human skin after irradiation therapy. *Exp. Dermatol.*, 13: 364–371.
- Roberts, I.S.D., Brenchley, P.E.C. 2000. Mast cells: the forgotten cells of renal fibrosis. *J. Clin. Pathol.*, 53: 858–862.
- Rubin, E., Gorstein, F., Rubin, R., Schwartz, R., Strayer, D. 2005. Rubins' pathology, 4th edn, Chapt. 3. Lippincott Williams & Wilkins. 62 Pp.
- Santos, P.P., Nonaka, C.F., Pinto, L.P., de Souza, L.B. 2011. Immunohistochemical expression of mast cell tryptase in giant cell fibroma and inflammatory fibrous hyperplasia of the oral mucosa. *Arch. Oral Biol.*, 56(3): 231–7.
- Shahrabi Farahani, S.H., Navabazam, A.R., SadrAshkevari, F. 2010. Comparison of mast cells count in oral reactive lesions. *Pathol. Res. Pract.*, 206: 151–155.
- Shimizu, Y., Suga, T., Maeno, T., Tsukagoshi, H., Kawata, T., Narita, T., *et al.* 2004. Detection of tryptase, chymase cells in human CD34 bone marrow progenitors. *Clin. Exp. Allergy*, 34: 1719–24.
- Theoharides, T.C., Kempuraj, D., Tagen, M., Conti, P., Kalogeromitros, D. 2007. Differential release of mast cell mediators and the pathogenesis of inflammation. *Immunol. Rev.*, 219: 204.